

Date: 02.08.2025; 1404/05/11

Patient's Name: R.KH

Responsible Physician: Dr. Esfandbod

Patient presentation:

75 Y/O woman with

1. invasive micropapillary carcinoma of right breast :

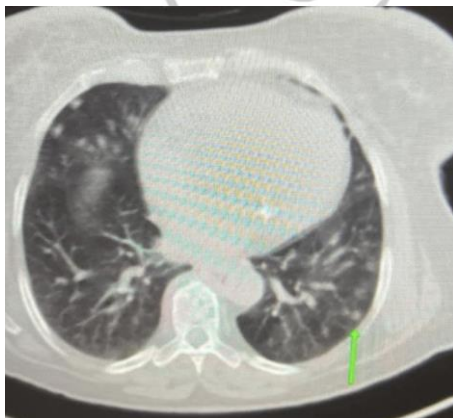
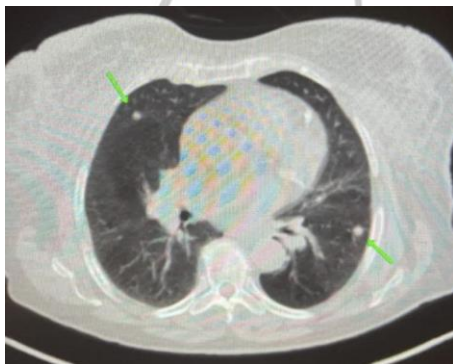
ER: 10% PR: negative

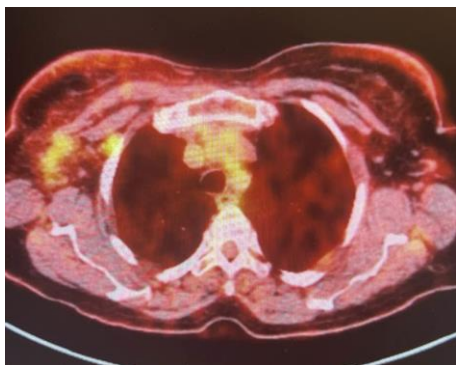
HER2: +++ Ki67: 57%

Underwent breast surgery: T: 2.5cm and LN: 8/16 Involved

2. intraductal papilloma of left breast which was excised and inferior margin of lumpectomy is suspicious for DCIS

3. In her PET-CT multiple lung nodules





Question:

What is the next step?

Recommended plan:

She does not need margin re-excision of left breast

PET review:

Multiple lung mets up to 9mm

Continue Herceptin and hormone therapy

Breast Disease Research Center