

Date: 21.12. 2024; 1403/10/01

Patient's Name: RZ

Responsible Physician: Dr. Esfandbod

Patient presentation: A 70 Y/O F underwent Lt. BCS + SLNB:

IDC III /T: 4.5cm/ER: 100%, PR: 80%, Her2: -, ki67:20%

She was presented in MDT, and according to that, she received endocrine therapy +XRT

Now, she presented with dyspnea, and she was investigated for metastasis

SPIRAL CHEST CT:

She has metastatic lesions in the liver, bone, and lung

Liver biopsy was done:

Metastatic carcinoma of breast origin

ER-, PR-, Her2-; GATA: +3, VIMENTIN +, PDL1+

She received chemotherapy and immunotherapy, but the disease progressed under treatment, and diffuse skin lesions

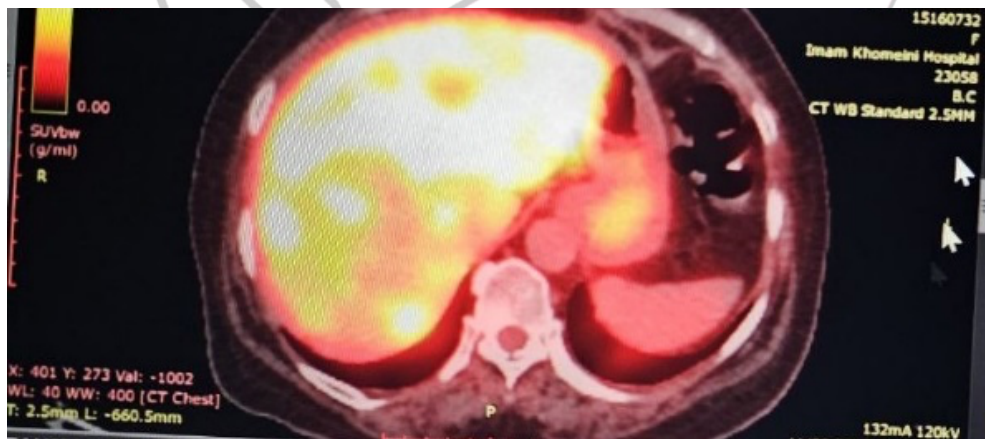
Biopsy of skin lesion:

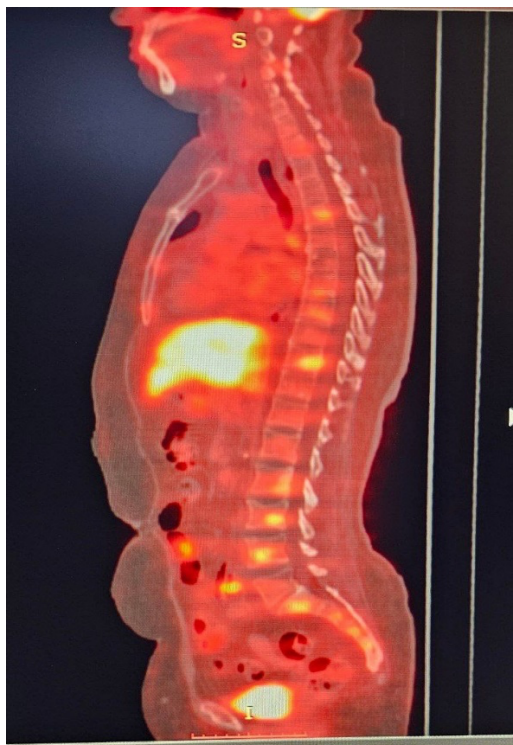Lichen planus-like due to immunotherapy

Question:

Best Treatment?

Recommended plan: Re-biopsy / Review of IHC / Check for BRCA





PET SCAN shows liver & bone metastasis

مركز بحوثات بيماء

Breast Disease Research Center