

Date: 14.12. 2024 ; 1403/09/24

Patient's Name: TS

Responsible Physician: Dr. Omranipour

Patient presentation: A 58 Y/O F, familial history positive (breast cancer in her mother and her aunt, ovarian cancer in her aunt); a known case of Lt. breast cancer, She underwent Lt. BCS+SLNB (1395):

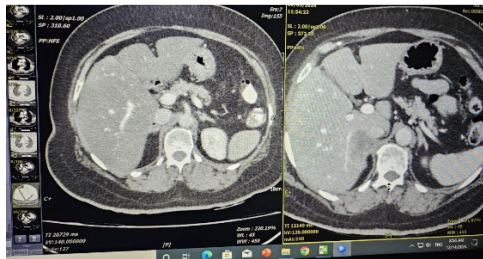
IDC II/III, ER: 90%, PR: 20%, Her2: -, Ki67:80%

She received adjuvant therapy /
bilateral oophorectomy (1398)

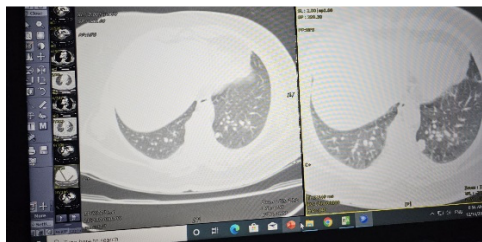
Lung metastatic nodule; confirmed by CT guided CNB(ER-,PR-,Her-,ki67:30%) (1400)

Abdominal CT (1403):

Large mass in the right adrenal that invades to liver



The CT Scan shows an adrenal mass growing



Chest CT shows lung nodules are bigger than previous

Question: What is the best treatment?

Recommended plan: The lung nodule & adrenal mass were larger than before

Adrenal mass biopsy and adrenal function test were recommended

