

Date: 15.03. 2025; 1403/12/25

Patient's Name: LH

Responsible Physician: Dr. Harirchi

Patient Presentation:

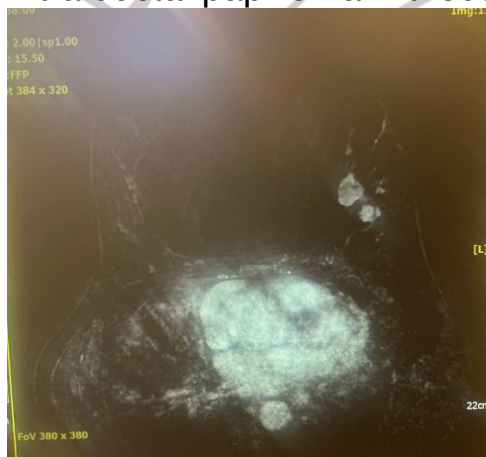
A 45 Y/O F, Presented with Lt. breast discharge

MG: multiple lesions in UOQ of Lt. breast

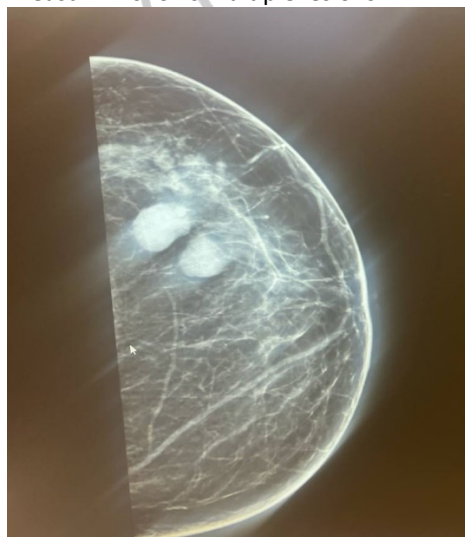
MRI: multiple heterogenous masses in Lateral & UOQ of Lt. breast (B4c)

CNB:

Intra ductal papilloma without atypia



Breast MRI shows multiple lesions



Lt. breast masses in mammogram

Question:

Best plan?

Recommended plan:

Surgical excision

