

Date: 08.03. 2025; 1403/12/18

Patient's Name: ED

Responsible Physician: Dr. Sarkardeh

Patient Presentation:

A 58 Y/O F.

Lt. retro areolar breast mass , 48*12 mm, lymphadenopathy in Lt. axillary
CNB:

IDC II/III, ER: -, PR: 30%, HER-2: -, Ki-67: 55%

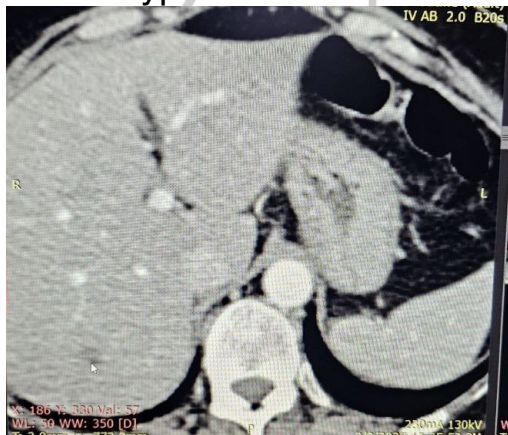
Ln: metastatic carcinoma

BONE SCAN:

No evidence of bone metastasis

CT SCAN:

12mm hypodense mass in liver



Question:

Best plan?

Recommended plan:

The quality of liver MRI is not perfect, another modality like PET ct, sonography + biopsy or a better liver MRI