

**Date:** 29.02. 2025; 1403/12/11

**Patient's Name:** SG

**Responsible Physician:** Dr. Moosavi

**Patient Presentation:**

A 44Y/O F, with history of Lt. breast cancer (1391):  
Neoadjuvant chemotherapy + BCS + SLN + XRT + Endocrine therapy  
(tamoxifen + letrozol)

IDC II/III, ER+, PR+, HER-2: +, Ki-67: 20% / T0N0  
1403:

isolated chest wall recurrence /2cm

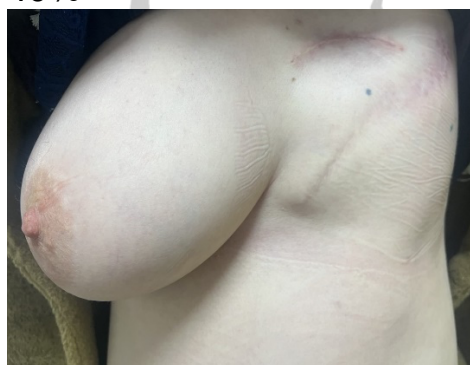IDC II/III ER +, PR +, HER-2: 1+, Ki-67: 10%

**PET Scan:**

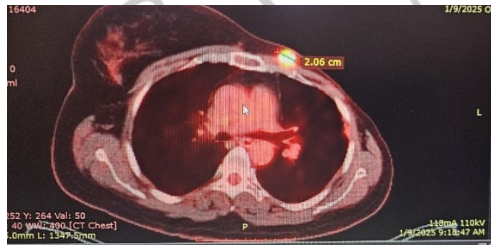
Uptake in chest wall / Mastectomy site

She underwent mass resection:

IDC II/III, Chest wall muscle involved, margin: free, T:18mm,T4a, Ki-67:  
40%



Pet scan shows recurrence in mastectomy site



**Question:**

Best treatment? Does she need to axillary dissection ?  
XRT?

**Recommended plan:**

XRT