

**Date:** 22.02. 2025; 1403/12/04

**Patient's Name:** FM

**Responsible Physician:** Dr. Mahmoodzadeh

**Patient Presentation:**

A 52 Y/O F, bilateral breast cancer  
1403/10:

Lt. BCS + ALND:

IDC I/III, T:12 mm, DCIS,

Skin & nipple involved, LVI+,

LN: 3 out of 11 LNS involved

Rt. BCS:

IDC II/III, 3 foci :12 mm + 2mm + microinvasion

DCIS (EIC) 38\*36 mm, LVI-

Margins: very close to in situ component

Inferolateral margin re-excision:

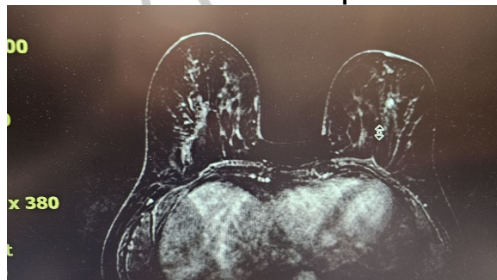
One focus involved

She underwent Rt. Re-excision + BCS:

Inferolateral margins: free

Inferior margin: high grade DCIS < 1mm (margin)

PET SCAN shows uptake in mediastinal



Breast MRI shows diffuse suspicious lesion in Rt. Breast

**Question:**

Next plan?

**Recommended plan:**

Breast MRI was reviewed: Suspicious multi focal lesions

Genetic Test + Chemotherapy + Mastectomy