

Date: 08.02. 2025; 1403/11/20

Patient's Name: GM

Responsible Physician: Dr. Tavakkol

Patient Presentation:

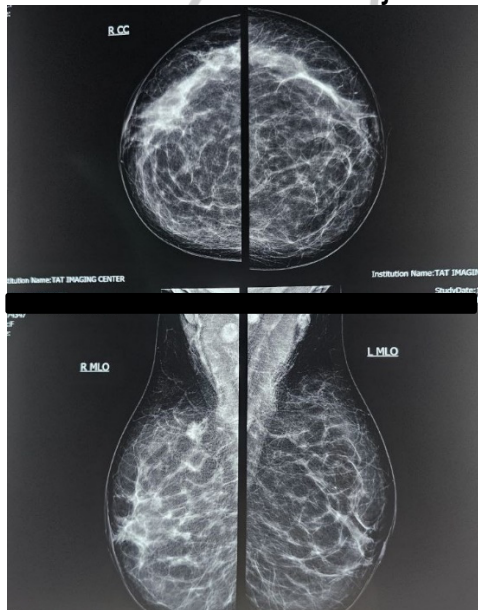
A 54 Y/O F with right breast mass at 10 o'clock, 18mm
CNB:

IDC, ER +, PR -, HER-2: 2+ (FISH: +),
Ki-67: 20%

Axillary LN: metastatic

BONE Scan & spinal MRI:
bone metastases (T7, T11)

She underwent neoadjuvant chemotherapy (8 sessions) + letrozole



Question:

What is the next plan? Surgery or endocrine therapy?

Recommended plan:

Breast surgery

Breast & spine radiotherapy
& endocrine therapy