

**Date:** 06.01. 2025; 1403/11/06

**Patient's Name:** MV

**Responsible Physician:** Dr. Esfandbod

**Patient Presentation:**

A 47 Y/O F,

known case of Lt. breast mass (1402):

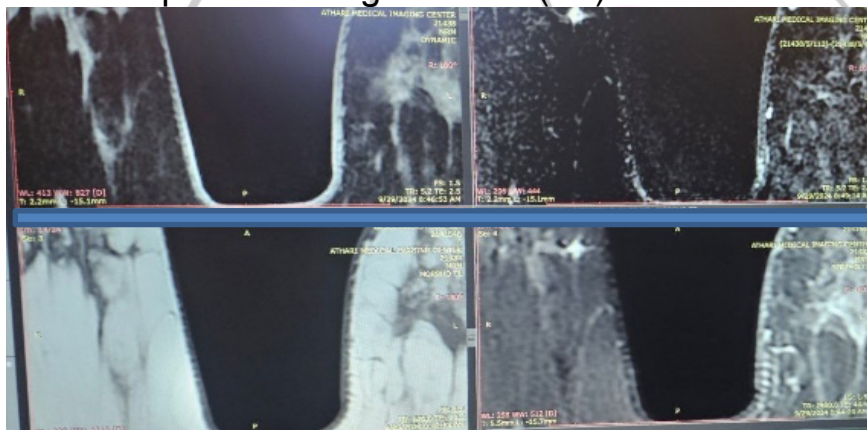
Lt. BCS + chemotherapy + XRT+ letrozole

Breast sonography (1403):

Rt. Breast mass, 2 o'clock, 6mm, suspicious (B4)

Mammography (1403):

Heterogeneous focal density with mild retraction of the overlying tissue in the inner part of the right breast (B0)



Breast MRI shows Rt. breast mass

**Question:**

What is the best treatment?

**Recommended plan:**

MRI reviewed: B4, suspicious mass, so core needle biopsy advised.