

Date: 18.01. 2025; 1403/10/29

Patient's Name: AR

Responsible Physician: Dr. Esfandbod

Patient Presentation:

A 77 Y/O F with positive familial history for breast cancer (her daughter),
Known case of Rt. Breast cancer

(17 years ago), Rt. MRM + Chemotherapy +XRT+ Letrozole (10 years)

Abdominopelvic ultrasonography was done for her because of a urinary infection.

Us finding:

Liver mass in Lt. lobe 35mm,

Liver MRI: Suspicion of liver mass

PET scan: hyperactivity in liver & Lt. adrenal

Liver biopsy: metastatic adenocarcinoma

CK7: +, CK20: -, CDX2: -, TTF1: -

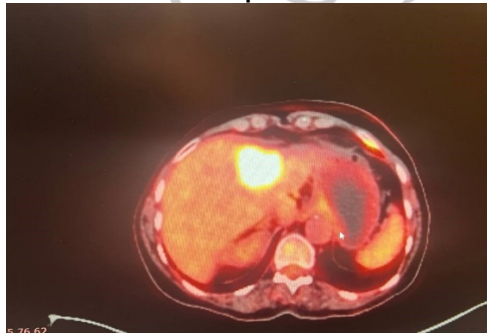
GAE3: -, PAX8:-,GATA3:-

Lab data:

الفافیتوپروتین :- , beta-hCG: -, CA19-9:69 (NL: up to 39)

Upper GI endoscopy & colonoscopy were done for her, and both of them were normal

She had a simple endometrial polyp that was excised



PET scan shows liver mass

Question:

Best treatment?

Recommended plan:

Liver mass excision.