

Date: 04.01. 2025; 1403/10/15

Patient's Name: SA

Responsible Physician: Dr. Elahi

Patient Presentation:

A 46 Y/O male with a negative familial history.

He is diabetic and presented with Rt. Axillary skin nodule
pathology of skin nodule (reviewed):

metastatic carcinoma of breast origin

CK7 +, CK20 -, GATA3 +, GCPFD15 +, ER 100%

PR 100%, Her2 -, Ki67 40%

PH/E:

Breast normal, Rt. Axillary incision with mild thickening, Rt. Axillary LN

2 cm

US:

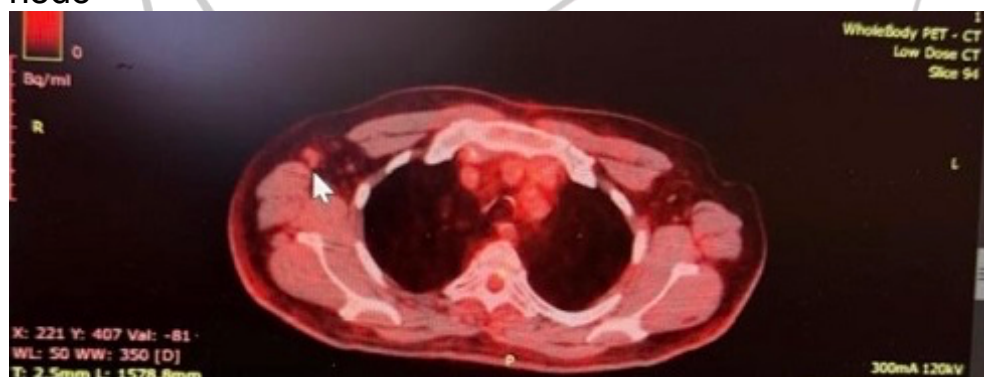
No breast mass, no lymphadenopathy

MRI:

Rt. axillary reactive lymph node 12*6mm

PET CT:

Rt. Axillary subcutaneous nodules SUV: 3.2, Rt. Axillary reactive lymph node



PET SCAN shows axillary lymphadenopathy

Question:

Next Plan?

Recommended plan:

Skin lesion excision + axillary LNs (level 2) dissection + genetic test