

Date: 19.07.2025; 1404/04/28

Patient's Name: M.KH

Responsible Physician: Dr.Miri

Patient presentation:

55 Y/O woman

1398 underwent breast cancer surgery (ER+ HER2-)

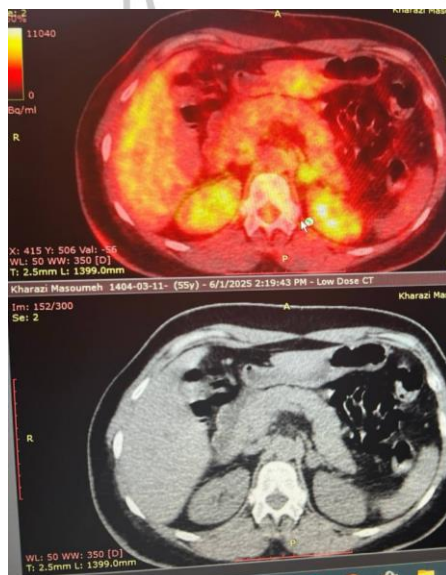
PET CT 1401:

Pleural effusion and LAP in iliac underwent LN BX: ER- HER2+

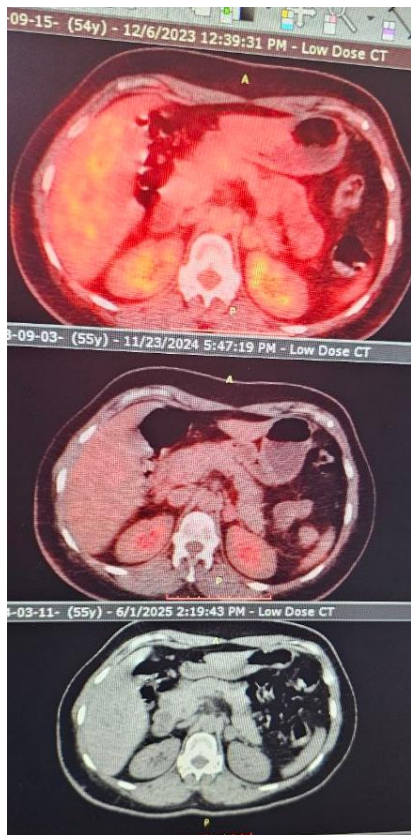
Underwent Anti HER2 therapy

PET CT in 1404:

Adrenal mass



In PET Review she had the same lesion in previous PET scans:



Question:

PET Review and what is the next step?

Recommended plan:

Adrenal Bx or Adrenalectomy