

Date: 10.5.2025; 1404/02/20

Patient's Name: M.Z

Responsible Physician: Dr. Esfandbod

Patient presentation:

64 Y/O woman presented with history of RA+ hypothyroidism

Lt Breast mass

US: nl / **MG:** nl

MRI:

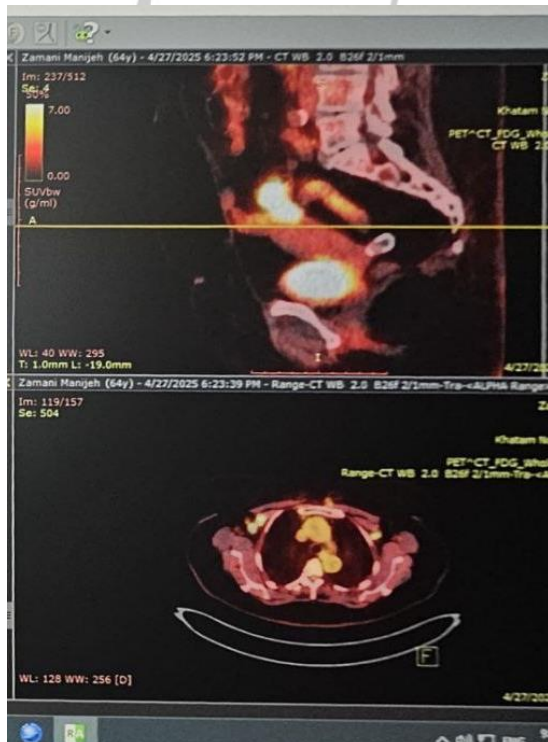
Enhancing masses in upper farzone (25mm) + adjacent non mass (15mm)

VAB: low grade Bcell lymphoma marginal zone lymphoma

PET CT:

Several bilateral cervical lymphomas + multiple abdominopelvic LN

+ Infiltrative lesions in fundus



Question:

Best plan?

Recommended plan:

Systemic therapy

