

Date: 03.05.2025; 1404/02/13

Patient's Name: F.J

Responsible Physician: Dr. Ebrahimi

Patient presentation:

45 Y/O woman with right axillary pain. Negative Family history

Us (11/1403):

A 24.5×15 matted cortex suspicious Ln in right Axilla

Cnbx: reactive lymphoid hyperplasia

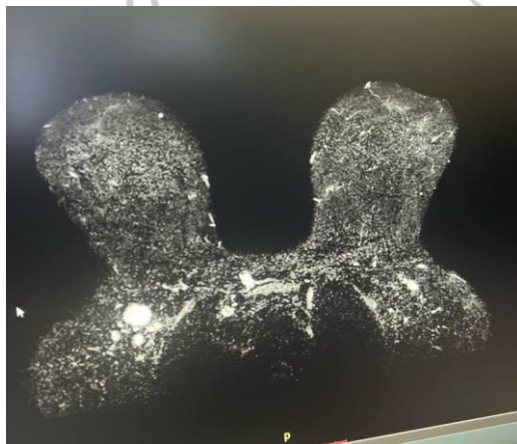
Control Us after AB treatment

(1404/01):

At least 4 suspicious Lns in right axilla

MRI (1404/01/31):

Multiple suspicious lesions in right UIQ and upper part as well as some level 1 suspicious axillary Lns, MRI guided biopsy recommended



Targeted Us (1404/02):

No suspicious breast lesion and some reactive level 1 axillary lymphadenopathy

Question:

Best plan?

Recommended plan:

Repeat Target US