

Date: 03.05.2025; 1404/02/13

Patient's Name: Z.M

Responsible Physician: Dr. Farazmand

Patient presentation:

47 Y/O

Mass feeling in left axilla

US and MRI: 13 mm mass in 2 oc

11 mm mass in 11oc

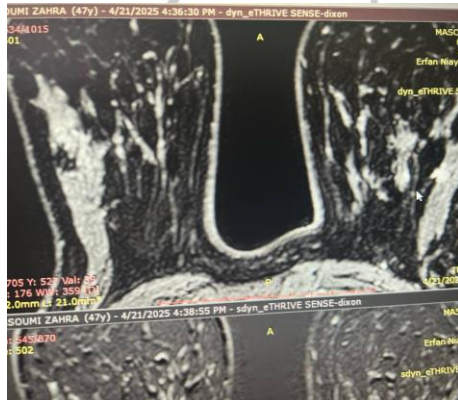
45 mm LAP

Breast masses were biopsied: FCC & fibroadenoma

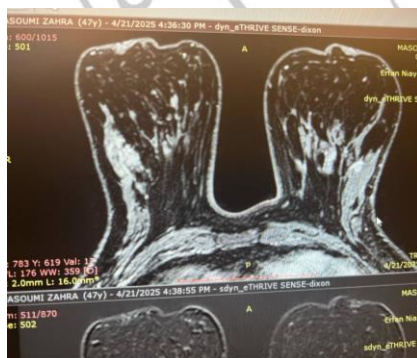LN: metastatic carcinoma ER100 PR30 HER-2:NEG Ki-67: 40%

Ct scans: ok The patient is reluctant to undergo surgical treatment

MRI:



Non mass enhancement and small mass



In axillary exam: N2

Recommended plan:

VAB+ in pathology result was benign tumor board suggestion is axillary surgery+ WBRT

