

Date: 03.05.2025; 1404/02/13

Patient's Name: P.F

Responsible Physician: Dr. Sarkardeh

Patient presentation:

47 Y/O woman

1395:

Lt Breast CA: invasive micropapillary carcinoma

Triple negative breast cancer 30%

Neoadjuvant + surgery (2cm G2-3 LN 3/12)

Adjuvant RT

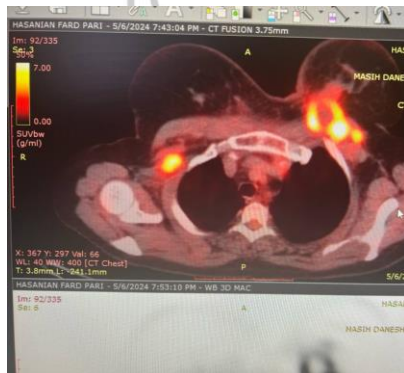1398:

Rt breast CA invasive ductile carcinoma Triple negative breast cancer

Ki-67: 35% PDL1+

PET: mediastinal LAP and small pulmonary nodule+ LAP in left axilla

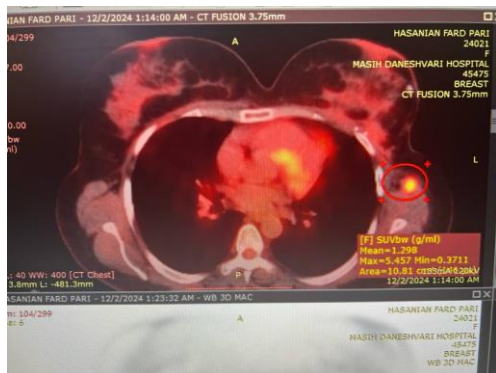
First PET scan:



Good response to Chemo and immunotherapy

Second PET:

No lung metastasis and good response in axilla



Question?
Best plan?

Recommended plan:

Immunotherapy+ Genetic testing +Surgery is not recommended

Breast Disease Research Center