

Date: 31.05.2025; 1404/03/10

Patient's Name: T.B

Responsible Physician: Dr. Omranipour

Patient presentation:

66 Y/O woman with history of bilateral mastectomy + right side ALND and left SLNB (1395)

She underwent adjuvant chemotherapy and radiation therapy

1403:

Mass and skin ulcer in left mastectomy bed

BX: Well-differentiated angiosarcoma

Mass excision and reconstruction with latissimus dorsi flap

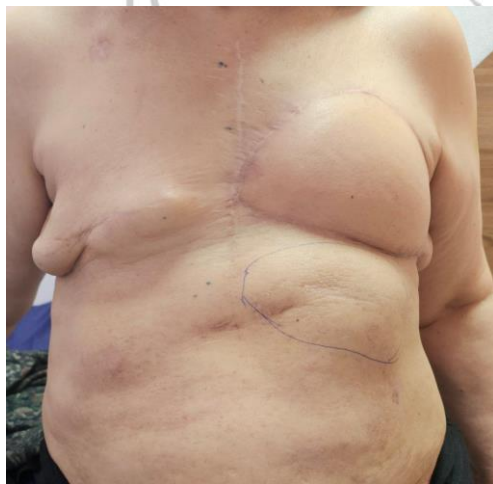1404:

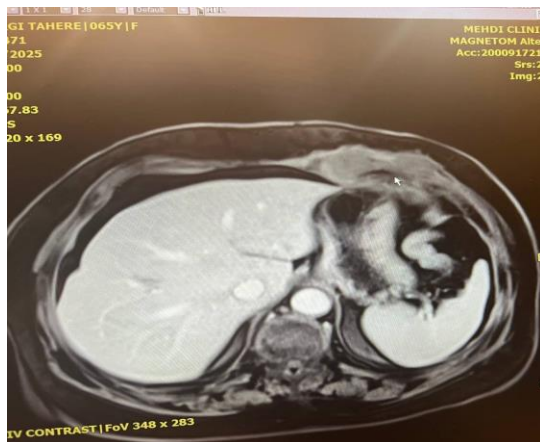
Mass and skin lesions in left upper abdomen

MRI: 65*28mm mass with extension to subxiphoid and intercostal muscle

CNB: mass: angiosarcoma (epithelioid type)

Skin BX: mild perivascular lymphocytic inflammation





Question:

Best plan?

Recommended plan:

Wide local excision + adjuvant XRT

Breast Disease Research Center