

Date: 9.11. 2024 ; 1403/08/19

Patient's Name: FP

Responsible Physician: Dr. Omranipour

Patient presentation: A 54 Y/O F presented with right breast mass in UOQ (5.7*10 mm).

CNB: Extra nodal marginal zone lymphoma

Systemic work up was normal

She was under observation without any treatment

The mass was growing since 1.5 years ago

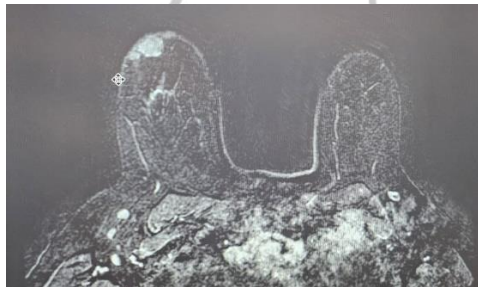MRI:

3 irregular masses right breast 11 o'clock 18*19mm/10*4mm/9*4mm with involvement of adjacent skin (B6)

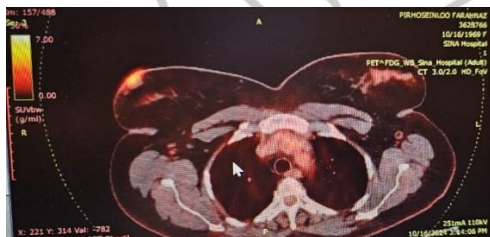
Speculated border oval mass measuring 11*6 mm in right breast 7-8 o'clock (B4)

CNB of 3 masses:

Extra nodal marginal zone lymphoma



Breast MRI shows right breast lesions



Right breast lesions in PET SCAN

Question:

What is the best option?

Surgery /XRT/Systemic treatment?

Recommended plan:

MRI was reviewed;

The new lesion in right breast 7-8 o'clock doesn't need biopsy, and XRT is better than surgery