

Date: 31.08.2024; 1403/06/10

Patient's Name: C.S

Responsible Physician: Dr. Harirchi

Patient presentation: A 62-year-old woman has been undergoing chemotherapy since two years ago due to cervical lymphadenopathy and an enlarged spleen with a diagnosis of LBCL. Currently, she has progressive enlargement of the right breast and axillary lymphadenopathy. In the examination, a mass was found in the upper outer part of the right breast with castration to the armpit and skin lesions.

Question:

Is mastectomy recommended?

Recommended plan:

- MRM was not recommended.

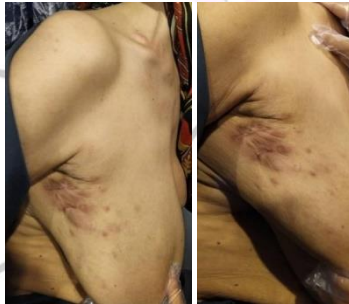

Figure 1 & 2: Right breast mass and supraclavicular lymphadenopathy.

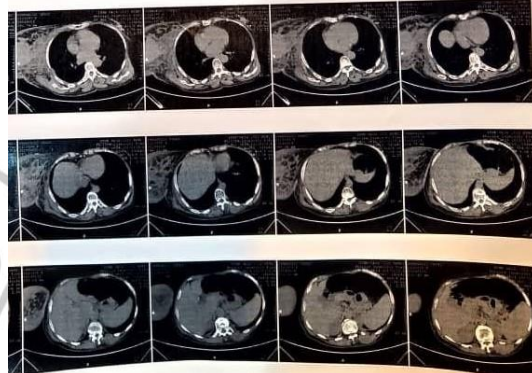


Figure 3: CT scan shows infiltrative lesion in right breast and axillary(R/o breast lymphoma).

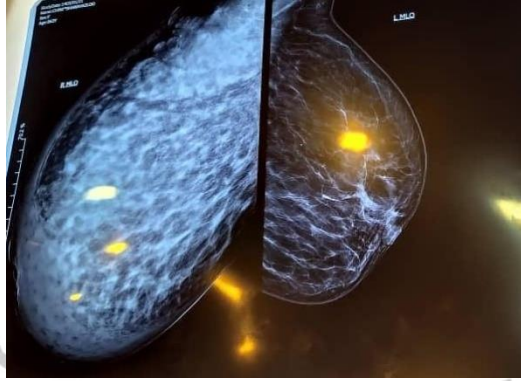


Figure 4: MG shows skin thickening in right breast and irregular border mass in UOQ and tail of the breast.

