

Date: 31.08.2024; 1403/06/10

Patient's Name: F.N

Responsible Physician: Dr. Miri

Patient presentation: 45-year-old woman with family history of prostate cancer in her father referred to clinic due to suspicious group and polymorphic micro calcification in mid zone and superior part of RT breast, US and breast MRI was unremarkable. VAB showed IDP with suspicious foci of LCIS and review the slides suggestive for ALH (E-cadherin: negative, CD14: positive, ER: positive).

Question:

What is the next treatment plan?

Recommended plan:

- Check the enhancement around the vacuum cavity with or without chemoprophylaxy

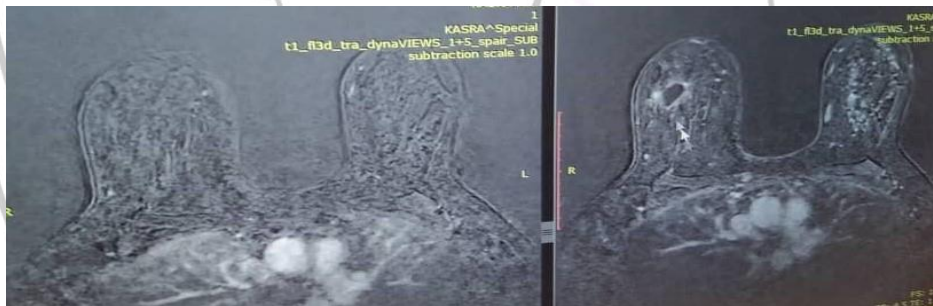


Figure 1: MRI shows enhancement around VAB cavity.

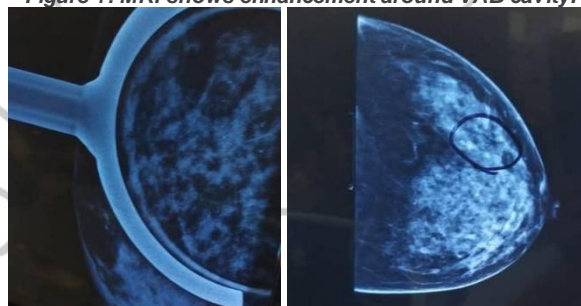


Figure 2 & 3: MG and focal spot view show suspicious microcalcifications.