

Date: 24.08.2024; 1403/06/03

Patient's Name: L.H

Responsible Physician: Dr.Alipour

Patient presentation: A 48 year old, without a family history of breast cancer, is being treated in 1399 following the diagnosis of right breast IGM. Due to 9 o'clock mass of the right breast in 1401 CNB was done and pathologic result confirmed fibroadenoma, after two years of treatment the mastitis improved. She underwent a CNB in TIR of this 1402 following right axillary lymphadenopathy, and pathologic results showed metastatic carcinoma with ER: positive, PR: positive HER-2: negative, Ki67: 25%, CK: positive, GATA: positive.

MRI and target breast ultrasound are performed and in addition to the right axillary lymph node, a 9 o'clock mass of the right breast has been seen, CNB showed fibroadenoma again.

Question:

What is the next treatment plan?

Recommended plan:

- 1- MRM
- 2- Due to thickness in transverse colon colonoscopy was recommended to r/o the IBD.

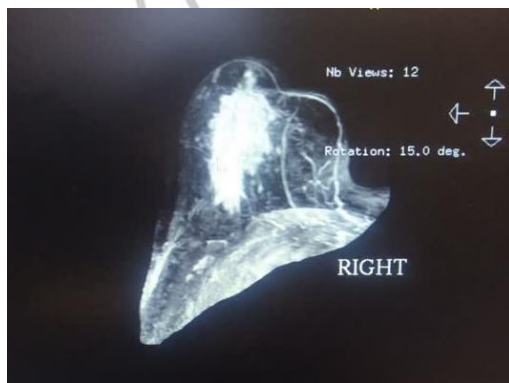

Figure 1: MRI shows non mass enhancement.

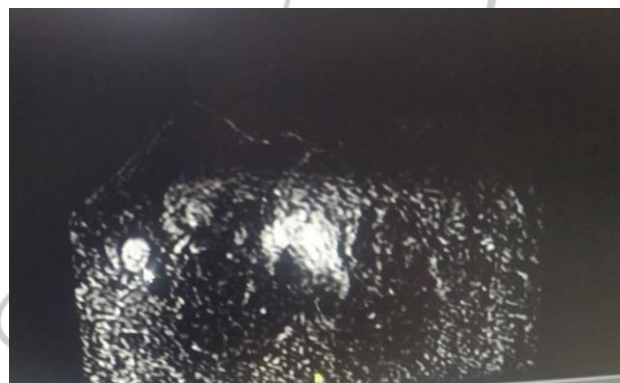


Figure 2: MRI shows suspicious axillary lymph node.

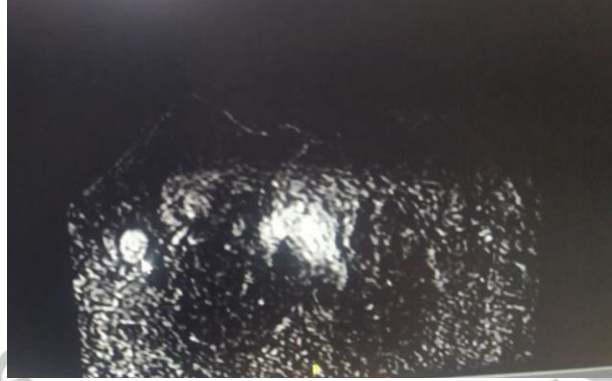

Figure2: MRI shows involved Axillary lymph nodes.

