

Date: 14.09.2024; 1403/06/24

Patient's Name: Z.A

Responsible Physician: Dr.Sarkarde

Patient presentation: A 39-year-old woman is being examined for a right breast mass. Focal asymmetry and microcalcification in the central part of the breast are reported in mammography, and two masses are seen in the bilateral retronipple area in ultrasound. Biopsy of masses shows stromal fibrosis and, focal squamous metaplasia, Columnar Cell Change, Usual Ductal Hyperplasia. In the breast MRI, Right NME is seen in the retronipple area (46mm). Two masses in the left breast are reported to be 8.5 and 8 mm (B4).

Question:

What is the next treatment plan?

Recommended plan:

- Excisional Biopsy

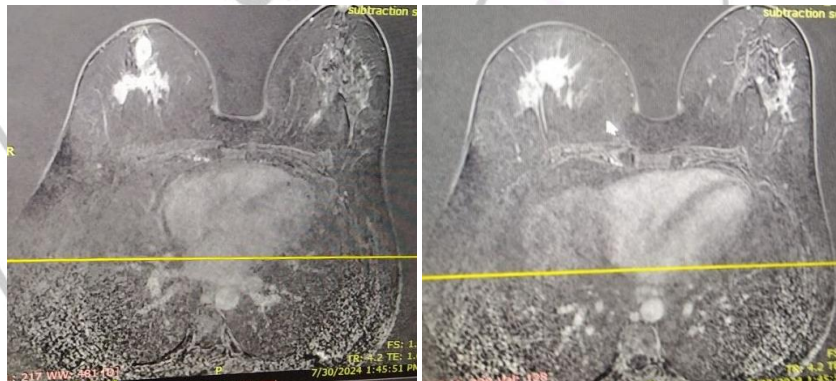


Figure 1 & 2: MRI shows suspicious right retroareolar mass.