

Date: 14.09.2024; 1403/06/24

Patient's Name: R.N

Responsible Physician: Dr.Lashgari

Patient presentation: A 41-year-old woman has been under work up since December 1402 following the palpation of a mass in the left axillary with increasing size. Mammography showed a suspicious left axillary lymph node and ultrasound showed a 40 mm lymph node with a solid cystic lesion below the lesion. Biopsy showed metastatic carcinoma with a possible primary origin of the kidney. PET scan showed the left axillary lymph node involvement of the skin of the area. (SUV:19.4) Re-view of slides showed undifferentiated adenocarcinoma.

Question:

What is the next treatment plan?

Recommended plan:

- Operation is recommended.

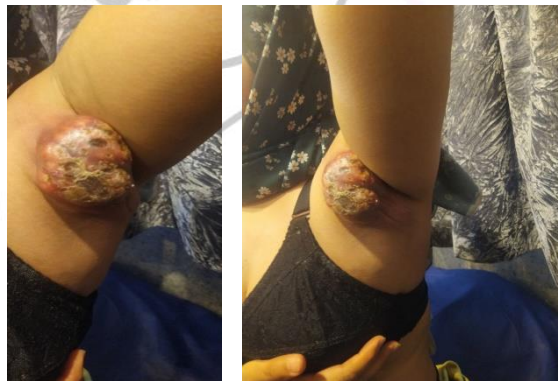

Figure 1 & 2: Left axillary mass.

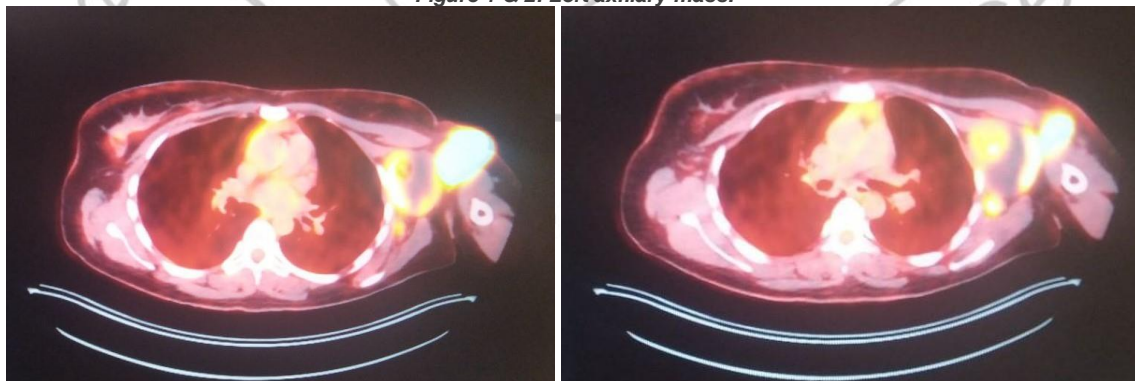


Figure 3 & 4: PET CT scan shows hyper metabolic mass in axillary region.