

Date: 02.11.2024; 1403/08/12

Patient's Name: F. I

Responsible Physician: Dr.Sarkardeh

Patient presentation: A 61-year-old woman presented with microcalcification in UOQ of right breast. VAB was done for her 2 years ago (1401), DCIS (intermediate), ER: negative, PR: negative. She didn't receive any treatment. The recent sonography and mammography are normal.

Question:

What is the next treatment plan?

Recommended plan:

- Mammography and MRI were reviewed (MG: B4, MRI: B3). Target sonography & FCMV are better to be done and then wire excisional biopsy.

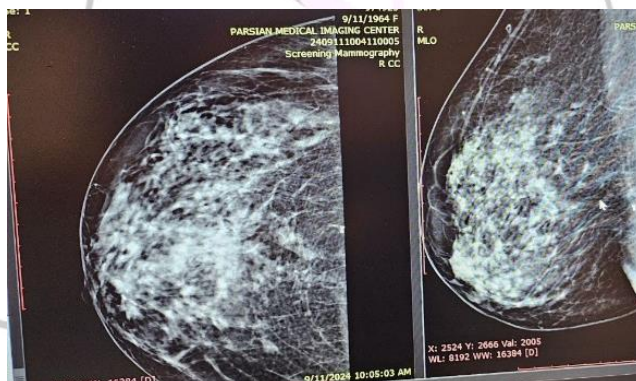


Figure 1: Mammogram shows dens breast.

Breast Disease Research Center