

Date: 02.11.2024; 1403/08/12

Patient's Name: S.A

Responsible Physician: Dr.Omranipour

Patient presentation: A 72-year-old woman with left breast mass who she underwent excisional biopsy: IDC, ER: 1%, PR: 1%, HER-2: +1, Ki67:25%. Abdominal CT & Liver MRI: Liver metastasis.

Question:

What is the next treatment plan?

Recommended plan:

- 1- Liver biopsy
- 2- Systemic therapy

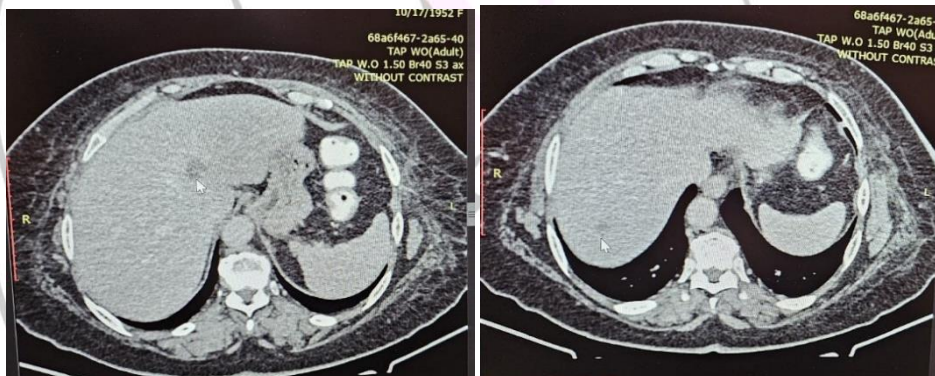


Figure 1 & 2: CT scan shows liver metastases.