

Date: 05.10.2024; 1403/07/14

Patient's Name: M.H

Responsible Physician: Dr.Esphandbod

Patient presentation: A 22-year-old with a left breast mass.

Sonography: Retroareolar, 50mm.

MRI: BIRADS: 4a.

CNB: Fibroadenoma.

Question:

What is the next treatment plan?

Recommended plan:

- Surgery (Excision)

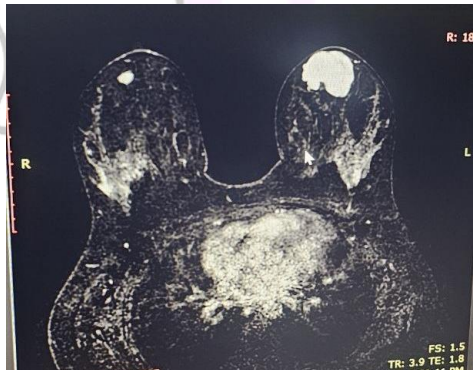


Figure 1: MRI shows left breast mass.

Breast Disease Research Center