

Date: 05.10.2024; 1403/07/14

Patient's Name: S.S

Responsible Physician: Dr.Alipour

Patient presentation: A 42-year-old woman with left breast mass (IDC, 38mm, ER: positive, PR: positive, Ki67: 40%, Lymph node: positive).

Abdominal CT: Liver lesion is suspicious.

MRI: Wasn't done.

CT scan of lung: Normal

Bone Scan: Multiple bone metastases.

Question:

What is the best treatment plan, curative or palliative treatment?

Recommended plan:

- Metastatic, Aromatase Inhibitor, Palbociclib.

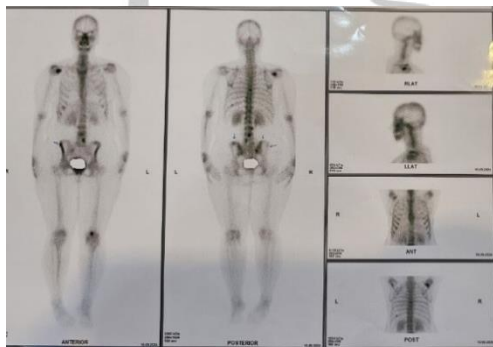


Figure 1: Bone scan shows multiple metastases.

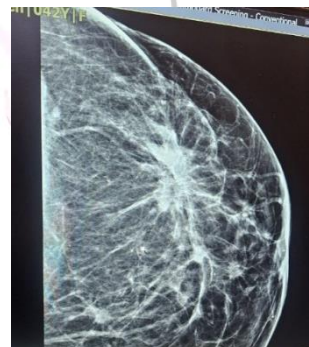

Figure 2: Mammogram shows left breast mass.

Breast Disease Research Center