

**Date:** 05.10.2024; 1403/07/14

**Patient's Name:** Z.SH

**Responsible Physician:** Dr.Omranipour

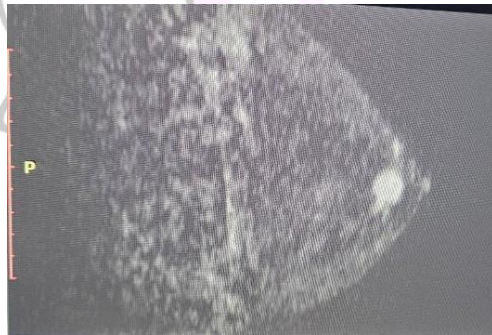
**Patient presentation:** A young woman with retroareolar mass (IDC, 15mm, LVI: negative).  
In final pathology the tract of CNB is involved by tumor.

**Question:**

What is the next treatment plan, surgery or chemotherapy?

**Recommended plan:**

- IHC, no need to re-excision.



*Figure 1: Mammogram shows retroareolar lesion.*

Breast Disease Research Center