

Date: 17.02.2024; 1402/11/28

Patient's Name: A.G

Responsible Physician: Dr.Sarkarde

Patient presentation: A 59 year-old woman with negative family history and nipple ulcer. She underwent BCS and SLNB.

Pathology: Nipple diagnosed as Paget disease.

Mammography: BIRADS: 1.

Sonography: One lymph node with cortical thickening in right axilla, no tumor in Breasts.

Pathology: IDC, Tumor size: 27mm, Grade: 3, Paget disease, Margins: free, SLNB: 0/4, ER: 20%, PR: negative, HER-2: triple positive, Ki67: 50%.

Question:

What is the next plan?

Recommended plan:

- 1- Breast MRI
- 2- Radiotherapy

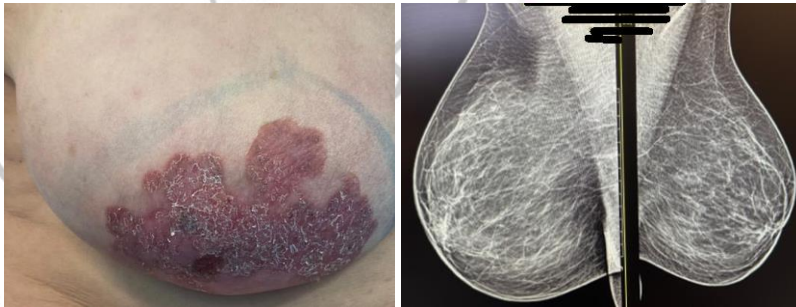


Figure 1: Skin lesion. Figure2: Mammography.