

Date: 27.01.2024; 1402/11/07

Patient's Name: F.E

Responsible Physician: Dr.Omranipour

Patient presentation: A 33 year-old woman with history of Breast cancer in her mother after age of 50. She underwent BCS and SLNB.

Mammography: Right breast mass, 12 o'clock.

Pathology: DCIS, 3mm invasive component, SLNB: 0/3, ER: negative, PR: 2%, HER-2: triple positive, Ki67: 15%.

Question:

What is the plan of adjuvant treatment?

Recommended plan:

- She benefits from Herceptin intake.

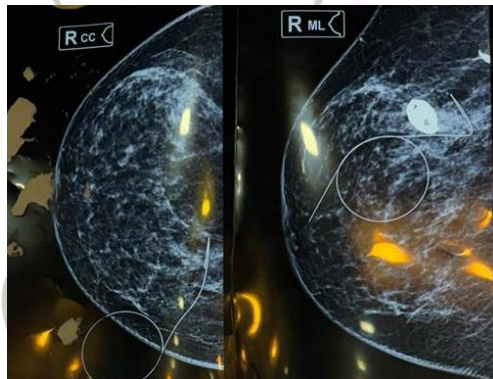


Figure 1: Mammography.