

Date: 15.06.2024; 1403/03/26

Patient's Name: A.E

Responsible Physician: Dr.Elahi

Patient presentation: A 42 year-old woman with negative family history and history of right breast mass excision 11 years ago, she had a recurrent mass after 1 year & growing slowly. She had a right lower huge mass on 1402.11. She underwent right lumpectomy 11*8* 6 cm specimen, phyllodes tumor intermediate, margin were undetermined on 1403.02.

Imaging: Right 4-8 o'clock solid cystic mass, 6*6 cm, BIRADS: 4C, right axillary Lymph Node cortical thickening B4a.

Breast CNB: Inflammatory cells

Axillary Lymph Node FNA: negative (fat)

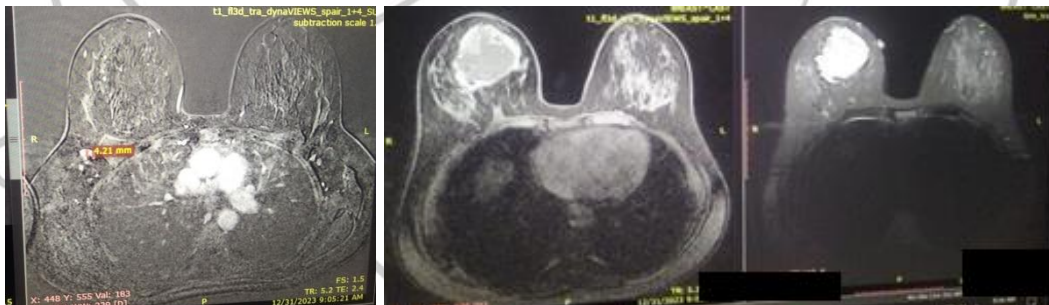
Review pathology: Malignant phyllodes.

Question:

What is the next treatment plan? Does she need reoperation or Adjuvant therapy?

Recommended plan:

- 1- Metastatic work up
- 2- Re-operation and re-excision of margin
- 3- Radiotherapy after surgery



Figures: MRI of breast shows Breast mass.

