

Date: 25.05.2024; 1403/03/05

Patient's Name: F.F

Responsible Physician: Dr.Esphandbod

Patient presentation: A 68-year-old woman who underwent BCS and SLNB in 1400, followed by chemotherapy and radiation therapy and treatment with Letrozole. According to the recent increase in tumor markers, PET scan was performed for the patient, and pulmonary nodules are reported. In the PET-CT scan, it was checked again, the nodules are not typical for metastasis.

Question:

What is the best treatment plan?

Recommended plan:

- Continue treatment with Letrozole.

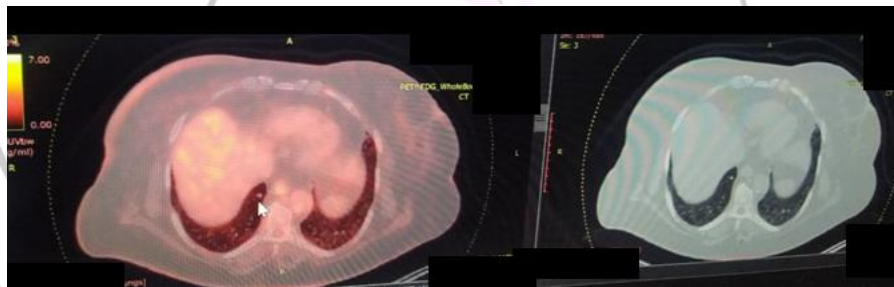


Figure 1: PET-CT shows Pulmonary nodule.