

Date: 11.05.2024; 1403/02/22

Patient's Name: M.H

Responsible Physician: Dr.Esphandbod

Patient presentation: A 38-year-old woman who underwent left breast MRM in 1402.12. CT scan showed nodule in the lung and lesions in the liver, PET CT scan showed increased uptake in the lung and cervical lymph nodes.

Question:

What is the treatment plan?

Recommended plan:

- 1- Adjuvant Chemo-radiotherapy
- 2- Follow-up US of neck, FNA if it is suspicious.

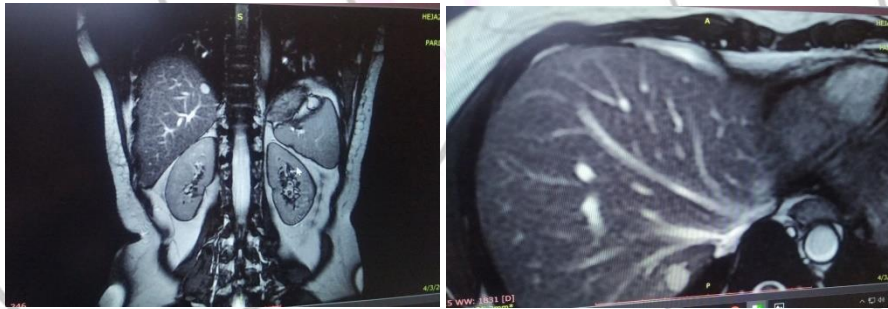

Figure 1 & 2: Liver lesions (Probably benign).

Breast Disease Research Center

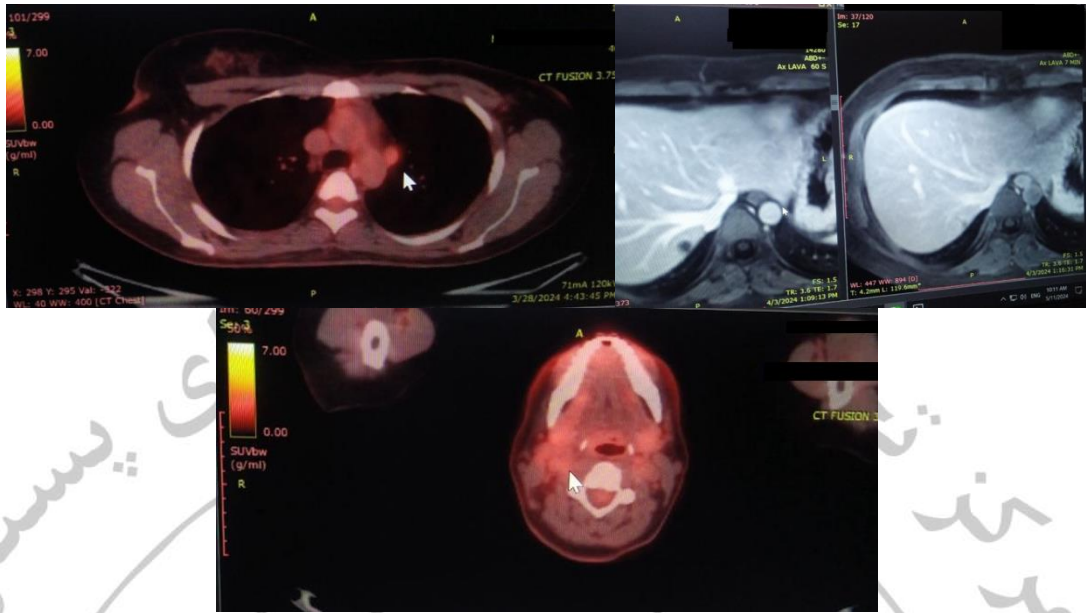


Figure 2, 3 & 4: Liver lesions, mediastinal lymph node and cervical lymph node.

Breast Disease Research Center