

Date: 06.07.2024; 1403/04/16

Patient's Name: F.GH

Responsible Physician: Dr.Esphandbod

Patient presentation: A 44-year-old woman with a history of locally advanced breast cancer in 1390 (ER: positive, HER: negative) was undergoing neoadjuvant chemotherapy followed by surgery, and radiation therapy and 10 years of Tamoxifen. Following blood sputum, she undergoes bronchoscopy, which shows endobronchial metastasis, and laser ablation was done. The patient is treated with Aromatase Inhibitor and surgical ovarian suppression (oophorectomy) and Palbociclib, but the disease has progressed. And numerous bone and liver metastases occur.

Question:

What is the best next plan?

Recommended plan:

- Add Fulvestrant

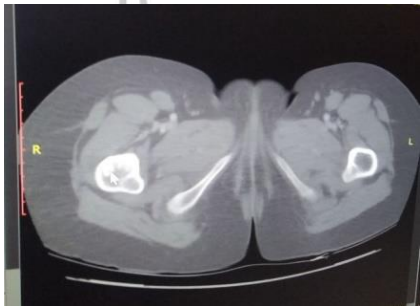

Figure1: CT scan shows metastasis in femur.

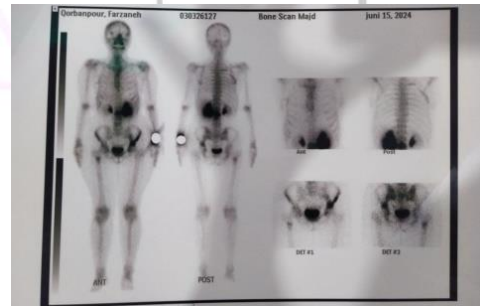


Figure 2: Metastatic sclerotic bone lesion.

Breast Disease Research Center