

Date: 06.07.2024; 1403/04/16

Patient's Name: F.B

Responsible Physician: Dr.Sarkarde

Patient presentation: A 69 year-old lady without family history of breast cancer with right breast mass sensation referred to clinic, Mammography showed hyper dense spiculated mass containing microcalcification at right UOQ anterior part with skin thickening (B5), Sonography findings include: at 11 o'clock areolar margin 27 mm mass, mild edematous changes with areolar and skin thickening ,highly suspicious mass /lymph node 47*30 in right Axilla, Lymph node in level 1, 35mm and 14mm in level 2, CNB showed IDC ,Grade: 2, LVI: negative, ER: negative, PR: negative, HER-2: triple positive, Ki67: 40%, and lymph node metastasis confirmed with pathology, in abdomen & pelvic CT scan multiple hetero/isodense mass with maximum diameter 55*45 was seen and Biopsy confirmed metastasis with breast origin (ER: negative, PR: negative, HER-2: triple positive) chemotherapy was started and In re-evaluation, the size and number of metastases have decreased (12mm in left lobe, 38,18mm in right lobe).

Question:

What is the best treatment plan?

Recommended plan:

- Continue chemotherapy

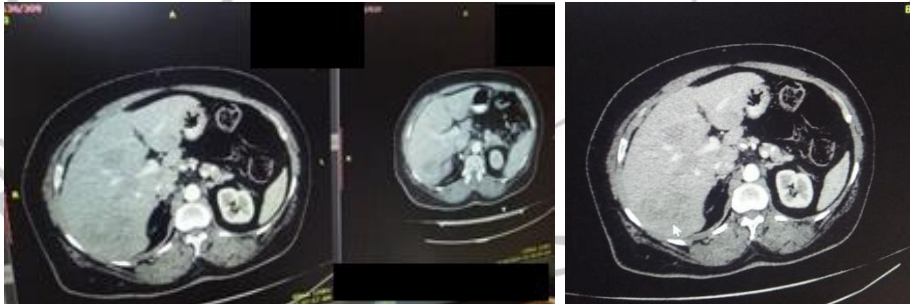


Figure 1&2: Multiple liver metastases in right and left liver lobe.