

Date: 29.06.2024; 1403/04/09

Patient's Name: H.S

Responsible Physician: Dr.Sarkarde

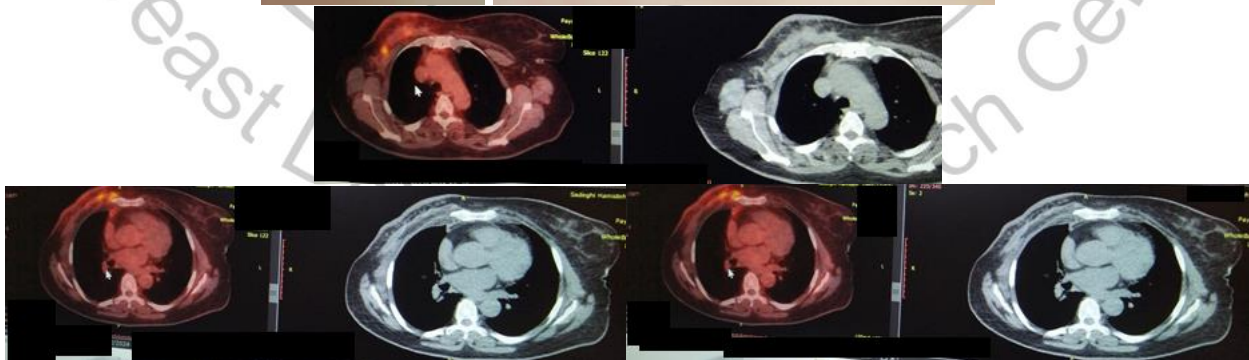
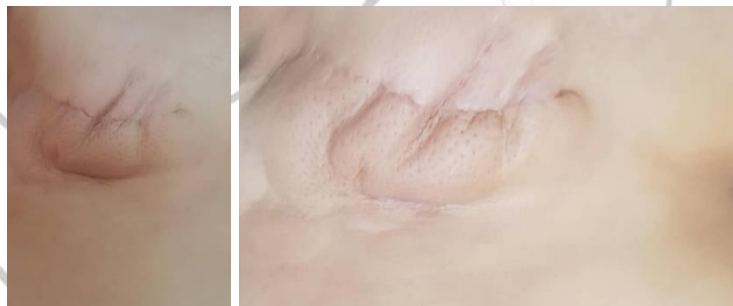Patient presentation: A 57-year-old woman who underwent right MRM in Ordibehesht 1402 (IDC, Tumor size: 35mm, Grade: 2, LVI: negative, ER: 33%, PR: negative, HER-2: triple positive, Ki 67: 17%, Nodes: 0/32). She underwent chemotherapy after surgery. In Azar 1402, she was examined for skin lesions and with recurrence at the mastectomy site, she underwent chemotherapy again. CNB of right mastectomy bed showed IDC, ER: 5%, PR: negative, HER-2: triple positive, Ki67: 70%, PET-CT scan showed post-surgical changes on the right side with multiple variable size masses and nodules (SUV 19.63) and hyper metabolic internal mammary lymph nodes (SUV 5.54).

Question:

What is the best next plan?

Recommended plan:

- Post mastectomy Radiotherapy is optional.



Figures: Show recurrence in right mastectomy bed.