

Date: 22.06.2024; 1403/04/02

Patient's Name: T.G

Responsible Physician: Dr.Esphandbod

Patient presentation: A 39-year-old woman presented with a feeling of stiffness in the upper outer part of the left breast. There are no suspicious findings in Mammography and MRI. Ultrasound suggests FCC patch in the area.

Question:

What is the best treatment plan?

Recommended plan:

- 1- Target US (second look)
- 2- CNB

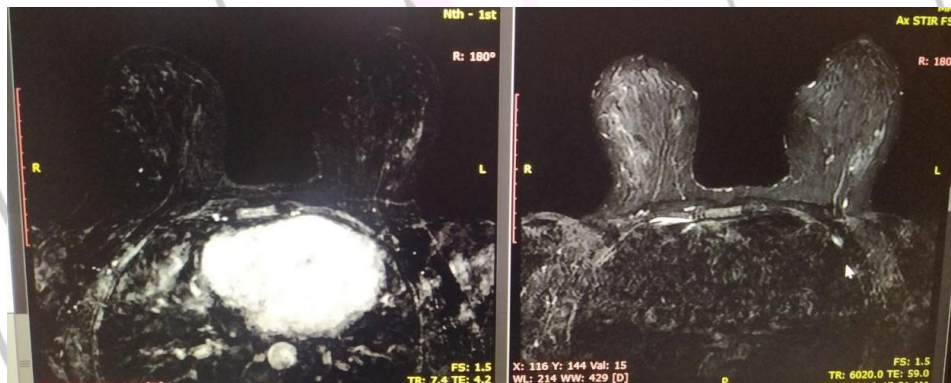


Figure 1: Normal MRI of Breast.

Breast Disease Research Center