

Date: 30.12.2023; 1402/10/09

Patient's Name: S.K

Responsible Physician: Dr.Sarkarde

Patient presentation: A 60 year-old woman with left breast erythema and edema.

Sonography:

16.5: Central of left breast skin and fibro glandular tissue edema in favor of mastitis, BIRADS: 3

23.8: Left erythema and edema no masses, BIRADS: 0.

MRI: Skin thickening, no masses, BIRADS: 4.

Skin biopsy: Skin tissue with mild perivascular lymphocytic infiltration with in dermis without epidermal ulceration, Negative for malignancy.

Left axillary lymph node CNB: No malignancy.

Question:

What is the next plan?

Recommended plan:

- 1- Large and deep Skin biopsy.
- 2- Based on general appearance of breasts reduction mamoplasty.

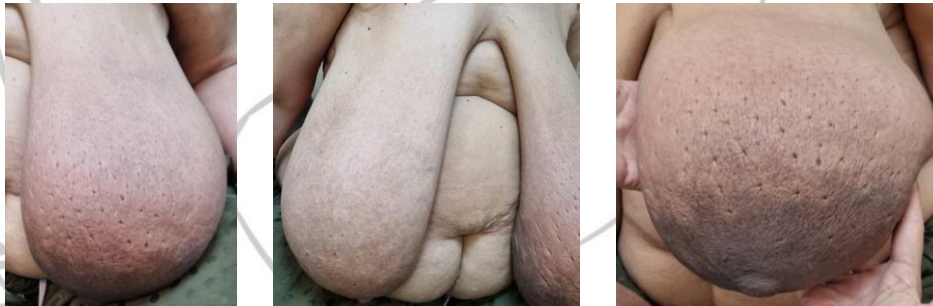

Figure 1, 2 & 3: Skin lesion.

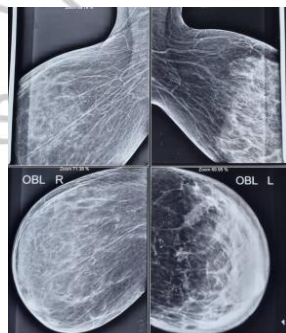


Figure 4: Mammography.