

**Date:** 13.01.2024; 1402/10/23

**Patient's Name:** F.Z

**Responsible Physician:** Dr.Mir

**Patient presentation:** A 44 year-old woman with history of Systemic lupus erythematosus (SLE) since 18 years ago.

In the last 2 years due to corona vaccination she had flare up of SLE as Renal impairment.

Now she is in remission. She has a mass in her right breast from 2 months ago. She underwent lumpectomy and SLNB.

**Treatments:** Celcept and Prograf (Tacrolimus) Prednisolone and Hydroxychloroquine.

**MRI:** Right UOQ 20\*20 mm non-mass enhancement in favor of diffuse papillomatosis.

**CNB:** Intraductal papilloma and micro calcification.

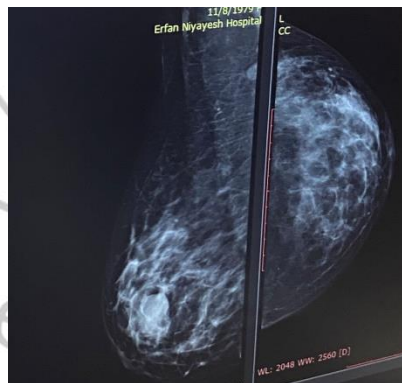
**Pathology:** Papilloma and DCIS, Tumor size: 18mm, Grade: 2, ER: 30%, PR: 20%, Margins: free, SLNB: 0/1.

### **Question:**

What is the next plan?

### **Recommended plan:**

- 1- Compare MRI with sonography and mammography of before surgery, before surgery then,
- 2- Follow-up sonography, if it is normal, just continue follow-up.



*Figure 1: Mammography.*

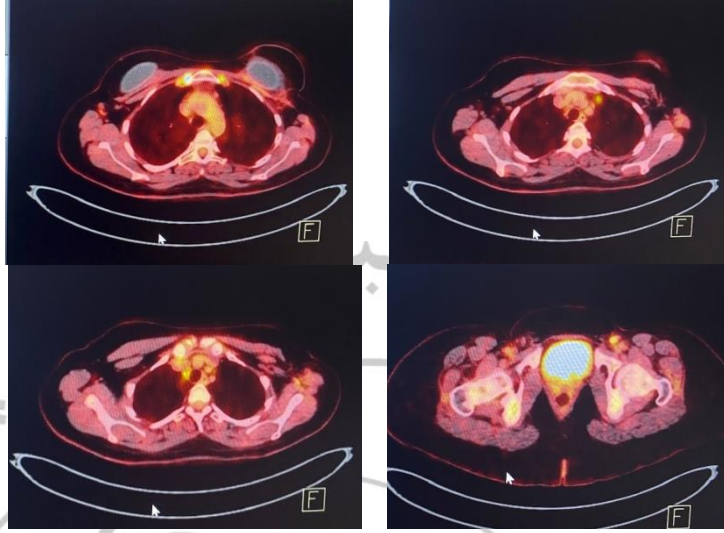


Figure 2, 3,4 & 5: PET CT shows mediastinal node.

