

Date: 13.01.2024; 1402/10/23

Patient's Name: M.J

Responsible Physician: Dr.Omranipour

Patient presentation: A 56 year-old woman with positive family history of her aunt.

Sonography:

Breast:

Left: 12*4mm focally dilated duct, BIRADS: 4b, Retro areolar 4b

Right: distortion in upper part

Axilla: Normal.

MRI:

Left: 15*13mm cyst in UIQ of breast,

Right: 20*15 mm DCIS in breast.

Vacuum biopsy:

Left breast: benign finding.

Right breast: IDC NOS, Grade: 2, ER: negative, PR: negative, HER-2: negative, Ki67: 15%.

CNB: Left retro areolar lesion Papilloma, no residue left.

Question:

What is the treatment plan?

Recommended plan:

- 1- She benefits from upfront surgery then,
- 2- Adjuvant therapy.

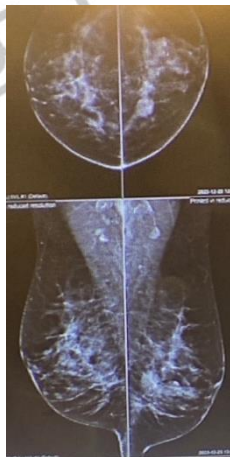


Figure 1: Mammogram.

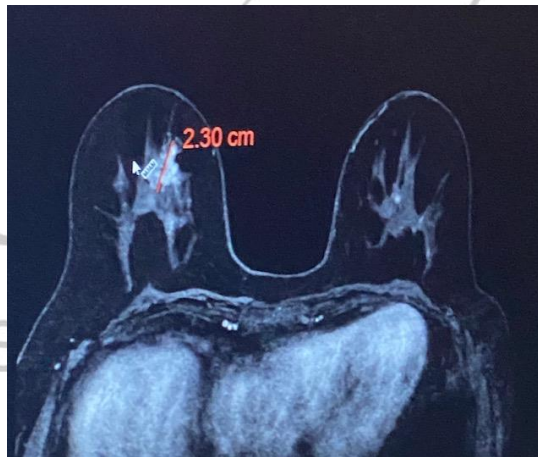

Figure 2: MRI shows breast mass.