

Date: 06.01.2024; 1402/10/16

Patient's Name: Z.J

Responsible Physician: Dr.Esphandbod

Patient presentation: A 54 year-old woman with left Breast mass. She underwent Mastectomy, Chemotherapy and Radiotherapy in year 1400. After 3 months she had recurrence in the contralateral Breast (IDC, ER: negative, HER-2: triple positive). She underwent Mastectomy and has taken Herceptin and Pertuzumab again. Now in follow up:
PET scan: 3 high uptake lesions in Liver.

Question:

What is the treatment plan?

Recommended plan:

PET scan review shows that Liver lesion isn't typically hyper metabolic.
Sonography of Liver:

If it is single Metastasis, operation is recommended,
If it is not suspicious mass, follow up.

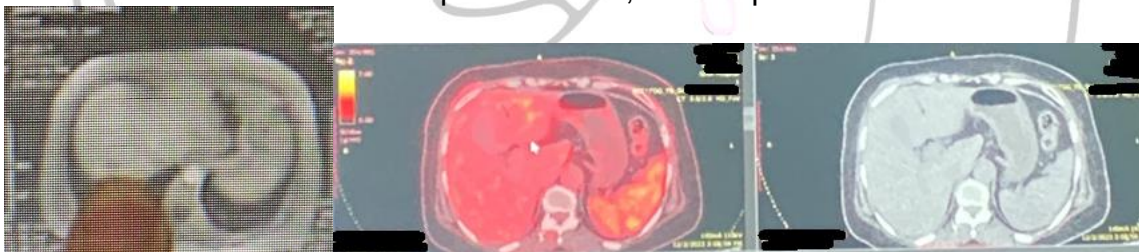


Figure 1, 2 & 3: PET CT shows Liver mass.