

Date: 06.01.2024; 1402/10/16

Patient's Name: T.R

Responsible Physician: Dr.Mohagheghi

Patient presentation: A 58 year-old woman with nipple discharge.

Mammography: 2 clusters of pleomorphic, Microcalcification in 7 O'clock and 11 O'clock retro-areolar.

CNB: Suggest for ADH or DCIS and questionable invasive component.

Question:

What is the treatment plan?

Recommended plan:

- 1- Mastectomy and SLNB
- 2- If BCS is considered bracketing before BCS.

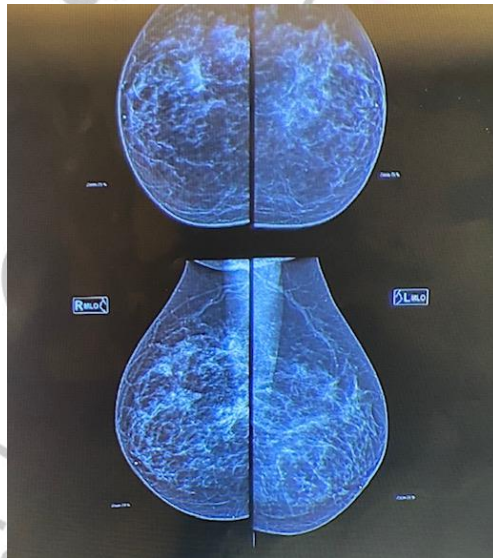


Figure 1: Mammography.