

Date: 10.08.2024; 1403/05/20

Patient's Name: N.M

Responsible Physician: Dr.Esphandbod

Patient presentation: A 51-year-old woman underwent BCS and SLNB in 1401. Due to margin involvement, she underwent mastectomy and radiation therapy after neoadjuvant chemotherapy. During follow-up, she was examined due to increased tumor markers. Chest CT scan showed large paratracheal and retrosternal Lymph nodes and biopsy of them confirmed metastasis from breast origin (triple negative).

Question:

What is the next treatment plan?

Recommended plan:

- Systemic treatment

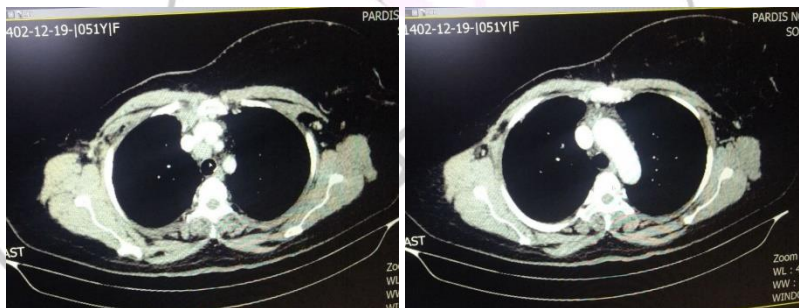


Figure 1 & 2: Chest CT scan shows pathologic retrosternal and paratracheal lymph nodes.