

**Date:** 10.08.2024; 1403/05/20

**Patient's Name:** K.Kh

**Responsible Physician:** Dr.Sarkarde

**Patient presentation:** A 55 year-old woman with multicentric IDC (US: 5 o'clock, 19 mm, 10 o'clock 5 mm, suspicious Lymph node: 17 mm, 7 mm. MG: Right breast spiculated mass in lower central and low density nodule in UOQ, dense lymph node in axillary) referred to clinic. CNB of mass showed IDC Grade: 2, luminal B, and FNA of lymph node was negative. MRI was done and showed two enhancing mass in 5 o'clock and 10 o'clock, and suspicious Lymph nodes in axillary region.

**Question:**

Is BCS possible in the patient?

**Recommended plan:**

- Metastasis work up
- Double lumpectomy was possible in this patient

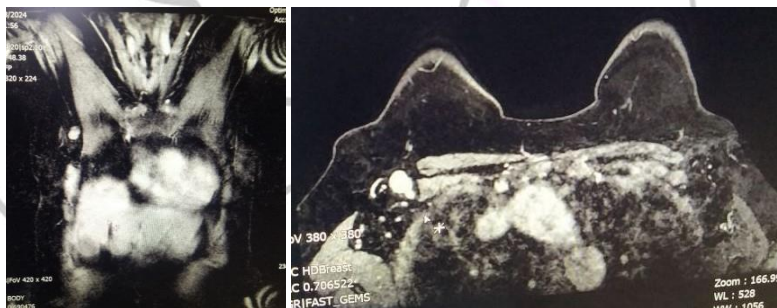


Figure 1 & 2: MRI shows suspicious axillary lymph node.

Breast Disease Research Center

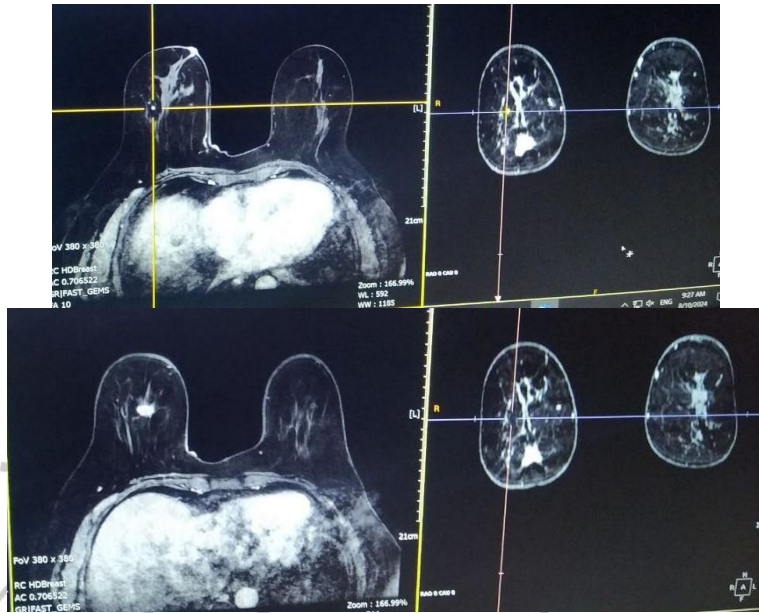


Figure 3 & 4: MRI shows two mass in right breast (6 o'clock and 10 o'clock)

Breast Disease Research Center