

Date: 27.07.2024; 1403/05/06

Patient's Name: L.B

Responsible Physician: Dr.Kheradmand

Patient presentation: A 44 year-old woman with history of breast cancer in 2nd degree referred to clinic due to right breast pain.in US solid cystic lesion was seen in right breast and CNB showed complex fibroadenoma, sclerosing adenoma, columnar cell change and PASH.MRI sowed multiple varying size cyst in both breast. The largest was 26 mm at deep zone right central and 24 mm at left central zone, smooth peripheral enhancing was seen in some of mentioned cyst that are complicated with associated regional NME around them. Review of MRI showed inflammatory right breast cyst.

Question:

What is the next treatment plan?

Recommended plan:

- VAB or surgical excision

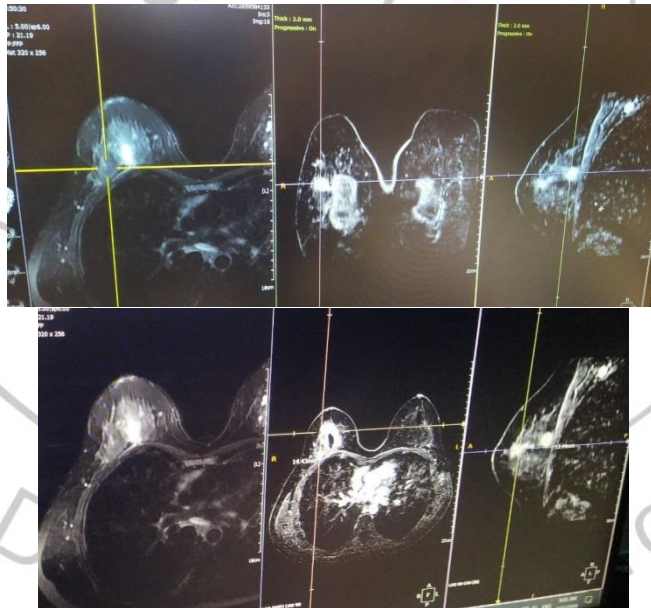


Figure 1 & 2: Cystic lesion with peripheral enhancing in breast MRI.