

Date: 20.07.2024; 1403/04/30

Patient's Name: B.S

Responsible Physician: Dr.Ebrahimi

Patient presentation: A 40 year old lady presented with a tender rapid growing mass in her left breast.

First Sonography: BIRADS 4

MRI: Extensive non-mass enhancement highly suggestive for DCIS, B5, targeted Sonography and Mammography: B4a, CNB: Acute on chronic inflammation and granuloma formation.

Question:

What is the next treatment plan?

Recommended plan:

- 1- Re-examination of MRI and target ultrasound is in favor of mastitis
- 2- Review the pathologic slides
- 3- Close follow up

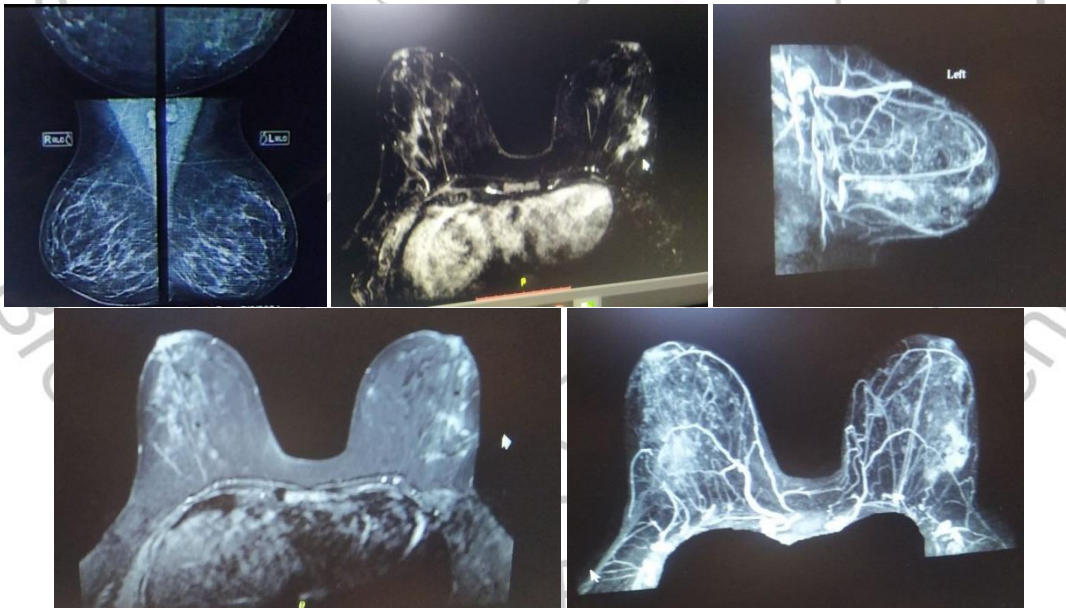


Figure 1, 2, 3, 4 & 5: MG and MRI show extensive NME in Left breast.