

**Date:** 13.07.2024; 1403/04/23

**Patient's Name:** M.A

**Responsible Physician:** Dr.Esphandbod

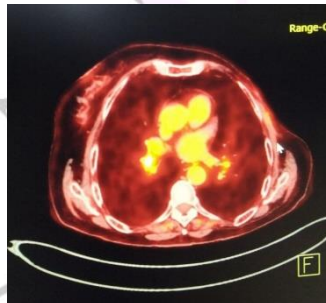
**Patient presentation:** A 83 year-old woman with history of left MRM followed by Tamoxifen treatment (4 years) underwent local excision and left liver lobe metastasectomy in 1402 (ER: positive, PR: positive, HER-2: negative).The patient was treated with Aromasin and Zometa. In the new PET scan, increased absorption is seen only in the mastectomy bed, but it was not found in the examination.

**Question:**

What is the best treatment plan?

**Recommended plan:**

- Target Sonography



*Figure1: PET-CT scan shows hyper metabolic lesion in mastectomy bed.*

Breast Disease Research Center