

Date: 16.03.2024; 1402/12/26

Patient's Name: S.R

Responsible Physician: Dr.Omranipour

Patient presentation: A 39 year-old woman with left Breast cancer in UOQ, Tumor size: 67*46*25mm.

CNB: IDC NOS, Grade: 2 ER: 95, PR: 45%, HER-2: negative, Ki67: 15%.

Bone scan: Focal uptake at the left side of mandible which was due to dental problems, increased activity of bilateral shoulders, knees and particularly ankles could be due to inflammation.

Question:

Does she have metastasis?

Recommended plan:

- Review showed normal vertebra degenerative changes in some bones and high uptake in left mandible is because of an old dental problem, not metastatic and suitable for upfront surgery.

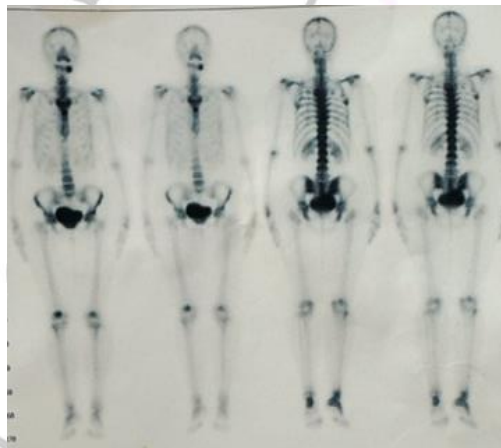


Figure1: Bone scan activity.

Breast Disease Research Center