

Date: 02.03.2024; 1402/12/12

Patient's Name: Z.S

Responsible Physician: Dr.Sarkarde

Patient presentation: A 47 year-old woman with right breast and arm edema

Mammography: BIRADS: 0, no definite pathology.

MRI: Rapid skin enhancement of right side, no evidence of mass or non-mass enhancement, Lymph nodes of both sides are normal, Axillary vein is normal, mild stasis

Biopsy: Fibrocystic tissue, mild usual ductal hyperplasia, Lymph nodes: negative, Left leg's skin lesion: Lentigo simplex

Question:

What is the treatment plan?

Recommended plan:

- Lymphangiography and rheumatologic evaluation

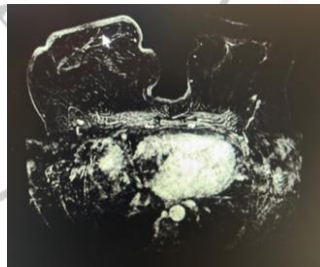


Figure1: MRI.

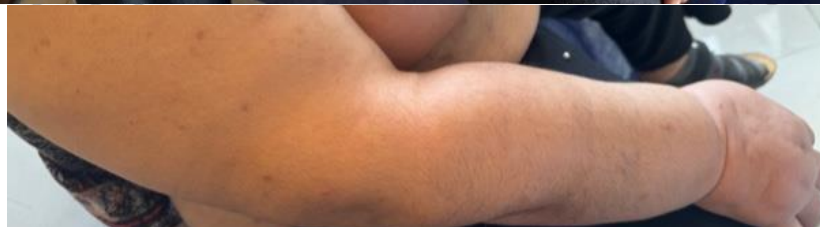


Figure 2 & 3: Lymphedema of upper limb.