

Date: 26.08.2023; 1402/06/04

Patient's Name: Z.N

Responsible Physician: Dr.Esphandbod

Patient presentation: A 36 year-old woman had undergone right MRM 4 years ago (IDC, Luminal) and Letrozole treatment till 6 months ago. Now she takes Palbociclib for Bone Metastasis. Liver Lesion showed on MRI and US in favor of metastasis.

Liver Biopsy: Low Grade small B Cell Lymphoma (Mantle).

PET scan: Solitary Liver lesion.

Question:

What is the treatment plan?

Recommended plan:

- Lymphoma Chemotherapy after Pathology review.

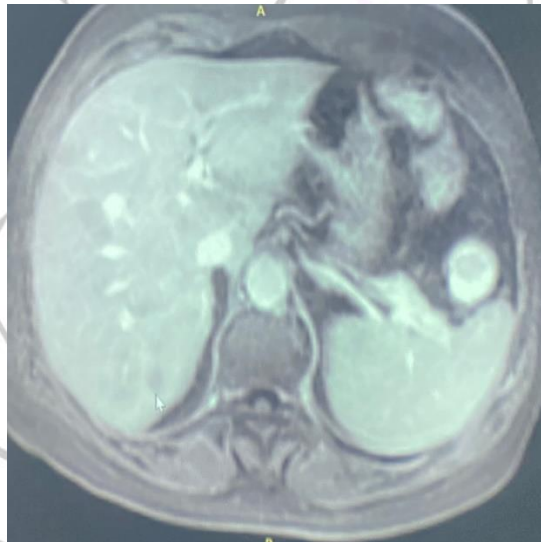


Figure1: Liver Lesion in CT scan